

# <sup>211</sup>At-Methylene Blue in Targeted Radiotherapy of Disseminated Melanoma

EVA M. LINK,<sup>1</sup> ADAM S. MICHALOWSKI,<sup>2</sup> AND FRANK RÖSCH<sup>3</sup>

<sup>1</sup>Department of Molecular Pathology, University College London Medical School, Cleveland St., London W1P6DB, UK; <sup>2</sup>MRC Cyclotron Unit, Hammersmith Hospital, Du Cane Rd., London W12 0HS; UK; <sup>3</sup>Institute of Nuclear Chemistry, Nuclear Research Centre, D-5170 Jülich, Germany.

Targeted radiotherapy with <sup>211</sup>At-methylene blue (<sup>211</sup>At-MTB) is a systemic treatment selectively directed at melanoma due to a high affinity of MTB to melanin synthesized in the tumor cells. Since MTB forms a strong complex with melanin, it is an effective carrier for a number of radioisotopes to be addressed to the tumor deposits of any size including individually dispersed melanoma cells. Thus, appropriately radiolabeled MTB can be used for either diagnosis or therapy of the neoplasm. As predicted and found in animal experiments, <sup>211</sup>At-MTB is most effective therapeutically. Histopathological investigations showed that the highly pigmented <sup>211</sup>At-MTB-treated tumors were characterized initially by perivascular oedema and hydropic degeneration of tumor cells followed by gradual development of extensive areas of coagulative necrosis. The necrotic tumor areas contained microvessels occluded by thrombi and tended to undergo microfocal calcification. Although melanoma-bearing animals successfully treated with <sup>211</sup>At-MTB did not reveal any adverse effects of the therapy, detailed toxicological studies were undertaken. No serious macro- or microscopic lesions were observed in normal organs of <sup>211</sup>At-MTB treated mice. Only the relative number of small lymphocytes in the groin lymph nodes in a minority of animals was variably reduced, most often in conjunction with the treatment of highly, but not poorly, pigmented tumors.

**Key words:** Melanoma, Targeted radiotherapy, Astatinated methylene blue, Histopathology

## INTRODUCTION

Cutaneous melanoma can recur at the site of surgical excision and be surrounded by satellite tumorlets. The invading tumor tends to spread through both the lymphatic and blood vessels. Distant metastases may arise early and in unpredictable sites. The metastatic dissemination calls for systemic treatment reaching all tumor cells, irrespective of whether singly dispersed and in circulation or forming tumor deposits of any size and location. This could be achieved using targeted radiotherapy whose effectiveness depends critically on a selective uptake of an appropriate radioisotope by melanoma cells. The selectiveness is ensured by the use of a radioisotope carrier with a high affinity for the tumor cells.

### METHYLENE BLUE AS A CARRIER FOR RADIOISOTOPES IN TARGETED RADIOTHERAPY OF MELANOMA

Since most melanomas are pigmented (Willis, 1967), the stably localized melanin constitutes a distinctive target within the tumor cells to be aimed at by means of a radioisotope carrier. Methylene blue (MTB) belongs to a family

of compounds characterized by a high affinity for melanin. Being of small molecular size, MTB—a well-established and non-toxic drug (Martindale, 1982)—penetrates with ease into melanoma cells and their melanosomes. It binds firmly and avidly to melanin (Potts, 1964) thus resulting in selective and lasting accumulation in melanoma lesions when administered systemically. Such a selective MTB uptake by melanoma cells has been abundantly demonstrated in tissue culture, as well as melanotic tumors in animals and man (Link and Rydzy, 1978; Link and Lukiewicz, 1982; Link et al., 1989; Dubois et al., 1992).

### Selection of Radioisotopes Suitable for Targeted Radiotherapy

The choice of radionuclides assuring the maximum efficacy of targeted radiotherapy is guided by their physical properties, of which the most important are high linear en-

---

Address reprint requests to Dr. E.M. Link, Department of Molecular Pathology, University College London Medical School, 46, Cleveland Street, London W1P 6DB, U.K.

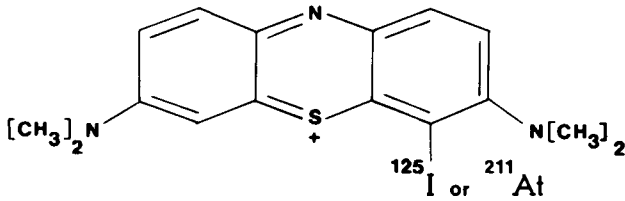


Fig. 1. The chemical structure of methylene blue as labeled with a halogen (either radioiodine or astatine).

ergy transfer (LET), short range of emitted radiation, relatively short half-life and safe daughter elements (Humm, 1986). Accordingly, anti-melanoma potential of the following three MTB radioanalogues has been investigated: <sup>35</sup>S (β-emitter), <sup>125</sup>I (Auger electron emitter) and <sup>211</sup>At (α-particle emitter) (Link and Lukiewicz, 1982; Link et al., 1989) (Fig. 1). Of the three, <sup>211</sup>At-MTB proved to be by far the most effective radioderivative and was therefore selected for further investigation (Link et al., 1989).

Astatine-211

<sup>211</sup>At was produced by the <sup>209</sup>Bi(α, 2n)<sup>211</sup>At nuclear reaction using 28 MeV α-particle external beam. <sup>211</sup>At (T<sub>1/2</sub> = 7.2 hr) decays by two pathways: 1) direct α-particle emission (41.9 ± 0.5%; 5.87 MeV) to <sup>207</sup>Bi (T<sub>1/2</sub> = 38 years), and 2) electron capture to <sup>211</sup>Po (T<sub>1/2</sub> = 0.52 sec), which is in transient equilibrium with <sup>211</sup>At and subsequently decays by the emission of α-particles, almost entirely of energy = 7.45 MeV, to stable <sup>207</sup>Pb. One α-particle is emitted per disintegration (Kassis et al., 1986) (Fig. 2).

A mean range of α-particles emitted by <sup>211</sup>At amounts to 60–65 μm (this corresponds to 3–6 cell diameters). Their high LET of 98.84 keV/μm unit density tissue is close to optimum (100 keV/μm), at which oxygen enhancement ratio (OER) of approximately 1 and maximum relative biological effectiveness (RBE) are achieved (Hall, 1994). These features of α-particles emitted by <sup>211</sup>At assure that the ra-

dioisotope carried selectively by MTB to melanoma cell deposits most of its energy within these cells with a highly efficient treatment achieved without associated damage to normal tissues surrounding the tumor.

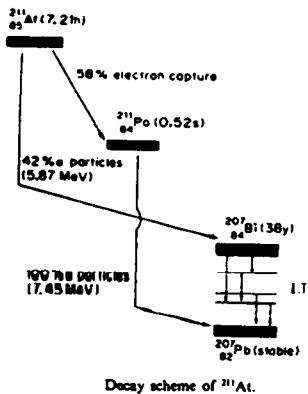
Therapeutic Efficacy of <sup>211</sup>At

Human melanoma-xenografted nude mice were used throughout to find out whether <sup>211</sup>At-MTB can scavenge blood-circulating melanoma cells, eradicate micrometastases and inhibit growth of solid tumors.

Intravenous injection of singly dispersed human melanoma cells obtained from solid tumors grown in mice was followed 1 or 7 days later by a single intravenous injection of 3.5 MBq <sup>211</sup>At-MTB. The number and average size of pulmonary tumor colonies were assessed 6–11 weeks after inoculation. Irrespective of the time interval between injections of the tumor cell suspension and <sup>211</sup>At-MTB, the number of lung colonies was reduced to below 10% of controls. The average colony size was diminished only when <sup>211</sup>At-MTB was administered 7 days after inoculation of melanoma cells (Link and Carpenter, 1990). The results led to the conclusions that <sup>211</sup>At-MTB can prevent the development of single blood-circulating melanoma cells and microtumors into macroscopic metastases and reduce growth rate of the viable neoplastic colonies. These findings applied to human melanoma with scarce melanin content, which was deliberately experimented upon to imitate the prevailing clinical pattern of pigmentation of metastatic deposits (Link and Carpenter, 1990).

More advanced clinical stages of tumor development were mimicked by subcutaneous transplantation of human melanoma fragments into nude mice subsequently treated by one or multiple intravenous injections of <sup>211</sup>At-MTB. The treatment invariably inhibited the tumor growth (Link and Carpenter, 1992). Its effectiveness depended primarily on melanin content and the size of lesions at the time of initiation of the therapy and varied from transient to permanent growth inhibition. Moreover, <sup>211</sup>At-MTB administration delayed the growth of melanoma metastases in

Astatine-211 ( <sup>211</sup>At ) :



Decay:  
 Half-life: 7.21 hrs  
 Mean energy: 6.8 MeV  
 Mean range in tissue: ~ 60 μm  
 Therapeutic LET<sub>00</sub>: ~ 100 keV/μm

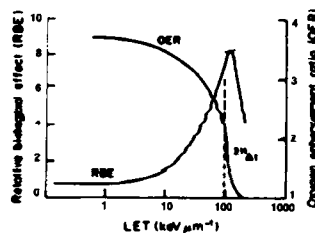
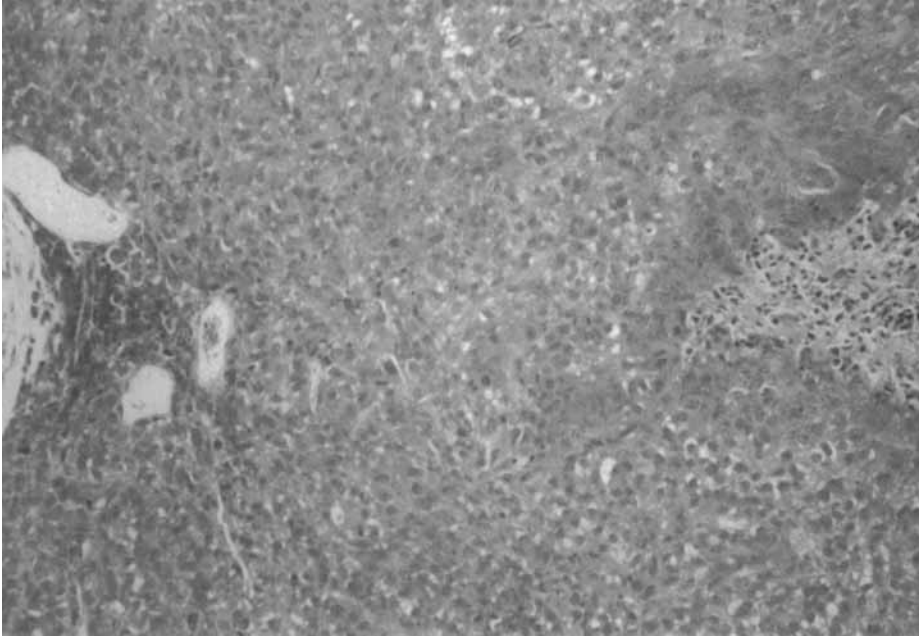

Fig. 2. Physical parameters of astatine-211 decay and the radiobiological properties of α-particles emitted by the radioisotope.



**Fig. 3.** Untreated xenograft of highly pigmented HX118 human melanoma grown subcutaneously in a nude mouse. Melanin is most clearly visible in the vicinity of subcapsular blood vessels on the left. A small area of fresh tumor necrosis occupies the mid-portion of the right margin. H&E,  $\times 160$ .

the regional lymph nodes that appeared spontaneously in most of the subcutaneous tumor-bearing mice (Link and Carpenter, 1992).

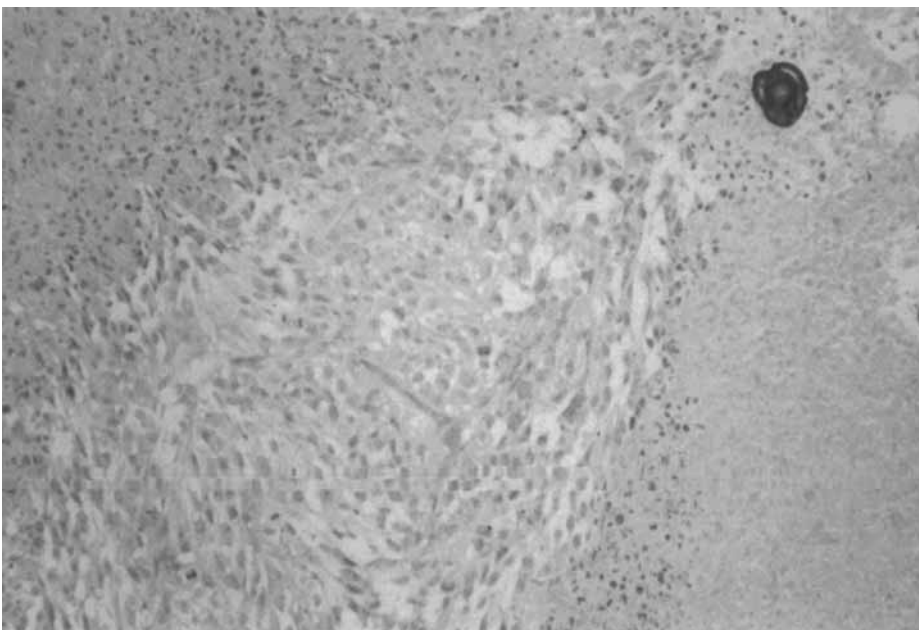
#### Microscopic Damage to Melanoma Tumors in $^{211}\text{At}$ -MTB-treated Mice

Nude mice with subcutaneously transplanted human melanomas (either highly or poorly pigmented) were treated with  $^{211}\text{At}$ -MTB and subsequently sacrificed and dissected over a period of 4 months (Fig. 3). Standard his-

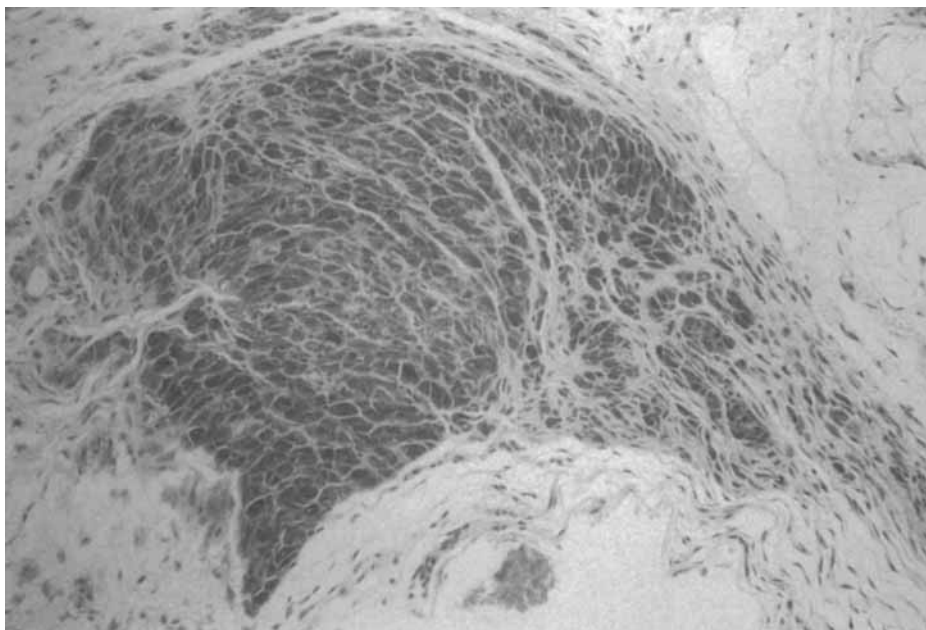
tological techniques were used to produce slides for light microscopic examination of the tumors, as well as several normal organs (see below).

Two types of highly pigmented melanoma response to the treatment were distinguished:

1. Early perivascular oedema with extensive vacuolar degeneration of tumor cells followed by wide-spread coagulative tumor necrosis. With time elapsed from the treatment, the unresorbed abundant necrotic tumor masses tended to calcify (Fig. 4). The remaining



**Fig. 4.** A xenograft of HX118 human melanoma 4 weeks after completion of  $^{211}\text{At}$ -MTB treatment. A round central nest of viable tumor surrounded by confluent areas of coagulative necrosis with psammomatous calcification (top right corner). H&E,  $\times 160$ .



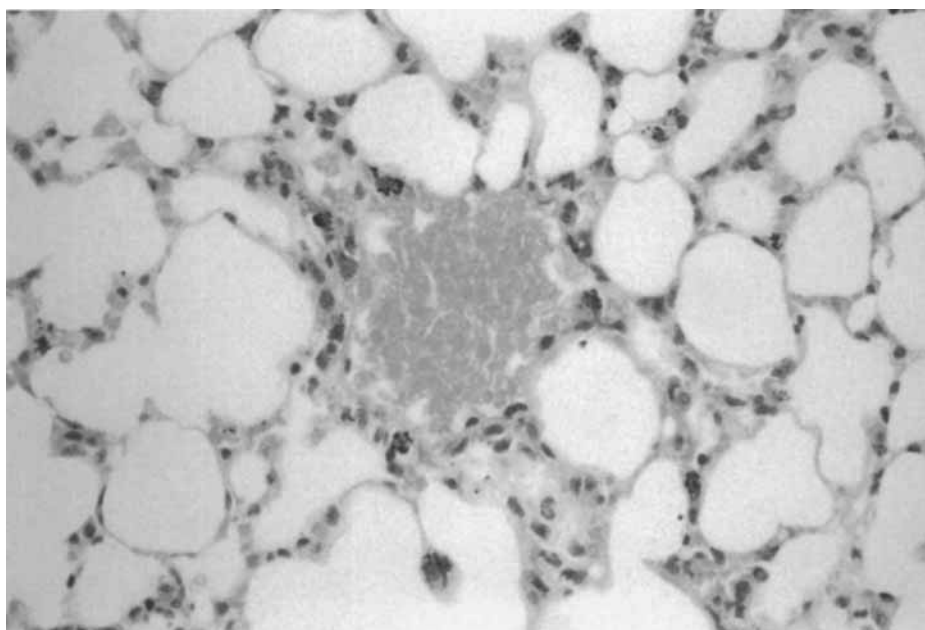
**Fig. 5.** Another xenograft of HX118 human melanoma 3 weeks after completion of  $^{211}\text{At}$ -MTB treatment. The remaining tumorlet consists of smaller than usual and heavily pigmented tumor cells separated by dense connective tissue. H&E,  $\times 160$ .

viable tumor did not differ in its microscopic appearance from that of untreated melanoma.

- Occasional early focal necrosis was liquefactive in nature. Foci of coagulative necrosis contained abundant deposits of melanin, which was also present in phagocytic cells of the host accompanying the blood vessels and accumulating in the fibrotic tumor capsule. Towards the end of the observation period the tumorlets consisted of heavily pigmented, round melanoma cells

with their nuclei smaller and denser than usual ("quiescent" tumor cells) and melanin-laden phagocytes (Fig. 5).

Unlike the highly pigmented melanoma, xenografts of the poorly pigmented variety did not show clear microscopic signs of damage after  $^{211}\text{At}$ -MTB treatment. The tumors of both control mice and those subjected to the therapy consisted of viable melanoma with fresh focal necrosis, often hemorrhagic.



**Fig. 6.** Melanin-laden phagocytic cells surrounding a pulmonary blood vessel and present also in the alveolar walls from a mouse bearing HX118 xenografts and treated with  $^{211}\text{At}$ -MTB 2.5 months before. H&E,  $\times 400$ .

### Microscopic Damage to Normal Organs in $^{211}\text{At}$ -MTB-Treated Mice

Microscopic examination of the  $^{211}\text{At}$ -MTB treated melanoma-bearing mice was extended to the following organs: the heart, lungs, stomach, small intestine, liver and gall-bladder, spleen, lymph nodes, kidneys, urinary bladder, thyroid, and adrenal glands. Treatment-related changes were observed only in the thyroid, lungs, and regional (groin) lymph nodes.

In some mice treated with astatinated MTB there was a focal interstitial oedema of the thyroid gland with scanty mononuclear infiltration, as well as moderate depletion and flattening of the epithelium lining a few follicles. In the lungs of mice bearing the highly pigmented melanoma and treated 2–3 months earlier, individually dispersed melanin-laden phagocytes were lodged in the alveolar walls and the adventitia of large blood vessels (Fig. 6). In some of the groin lymph nodes of  $^{211}\text{At}$ -MTB-treated mice the number of the cortical small lymphocytes was reduced.

In summary, a substantial therapeutic gain has been achieved at the expense of a negligible damage to normal organs thus providing a strong case for targeted radiotherapy of disseminated melanoma in man with  $^{211}\text{At}$ -methylene blue.

### ACKNOWLEDGMENTS

The financial support from the Cancer Research Campaign is gratefully acknowledged.

### REFERENCES

- Dubois, D., Ledermann, J.A., Link, E.M., Stauss, H. and Collins, M. (1992) Malignant melanoma. *Lancet*, 340:948–951.
- Hall, E.J. (1994) Linear energy transfer and relative biological effectiveness. *In: Radiobiology for the Radiologist*. IVth ed. Lippincott, Philadelphia, pp. 153–164.
- Humm, J.L. (1986) Dosimetric aspects of radiolabelled antibodies for tumour therapy. *J. Nucl. Med.*, 27:422–427.
- Kassis, A.I., Harris, C.R., Adelstein, S.J., Ruth, T.J., Lambrecht, R. and Wolf, A.P. (1986) The in vitro radiobiology of astatine-211 decay. *Radiat. Res.*, 105:27–36.
- Link, E.M. and Rydzy, M. (1978) Endoirradiation of neoplastic tissues by administered radioisotopes. *In: Proceedings of the Third Meeting of the Polish Biophysics Society*, p. 62.
- Link, E.M. and Lukiewicz, S. (1982) A new radioactive drug selectively accumulating in melanoma cells. *Eur. J. Nucl. Med.*, 7:469–473.
- Link, E.M., Brown, I., Carpenter, R.N. and Mitchell, J.S. (1989) Uptake and therapeutic effectiveness of  $^{125}\text{I}$ - and  $^{211}\text{At}$ -methylene blue for pigmented melanoma in an animal model system. *Cancer Res.*, 49:4332–4337.
- Link, E.M. and Carpenter, R.N. (1990)  $^{211}\text{At}$ -methylene blue for targeted radiotherapy of human melanoma xenografts: Treatment of micrometastases. *Cancer Res.*, 50:2963–2967.
- Link, E.M. and Carpenter, R.N. (1992)  $^{211}\text{At}$ -methylene blue for targeted radiotherapy of human melanoma xenografts: Treatment of cutaneous tumors and lymph node metastases. *Cancer Res.*, 52:4385–4390.
- Martindale (1982) *The Extra Pharmacopoeia*. J.E.F. Reynolds, ed., 28th ed. The Pharmaceutical Press, London, pp. 384–385.
- Potts, A.M. (1964) The reaction of uveal pigment in vitro with polycyclic compounds. *Invest. Ophthalmol. Visual. Sci.*, 3:405–416.
- Willis, R.A. (1967) The melanoma. *In: Pathology of tumours*. Butterworths, London, pp. 915–936.